

## CASE REPORT

# Isolated Non-Compacted Myocardium: Should We Consider the Presence of Extrasystoles as the Initial Manifestation?

Erivelton Alessandro do Nascimento,<sup>1,2</sup> Raphaella Nagib Carvalho Santos,<sup>3</sup> Fernanda Fraga Tolomelli Dutra,<sup>3</sup> Maria Gabriela Inocente Vitória<sup>3</sup>

*Centro Universitário de Volta Redonda,<sup>1</sup> RJ - Brazil*

*Instituto Estadual de Cardiologia Aloysio de Castro,<sup>2</sup> RJ - Brazil*

*Hospital Municipal Dr. Munir Rafful,<sup>3</sup> RJ - Brazil*

## Abstract

Ventricular non-compaction occurs due to failure in myocardial morphogenesis during the fetal period. Patients can have heart failure, as well as systemic complications due to thromboembolism and cardiac arrhythmias. Early diagnosis is essential. We present the case of an asymptomatic 49-year-old woman who initially manifested ventricular extrasystoles and heart failure with reduced ejection fraction and a myocardial noncompaction diagnosis.

## Introdução

The non-compacted myocardium, also known as spongy myocardium, is a distinct form of cardiomyopathy that occurs due to compaction failure during fetal development. It is characterized by prominent ventricular trabeculae and deep intertrabecular recesses, or sinusoids, in communication with the left ventricular cavity.<sup>1-5</sup>

It is currently classified as a primary genetic cardiomyopathy by the American Heart Association (AHA) and characterized as an unclassified cardiomyopathy by the World Health Organization (WHO) and the European Society of Cardiology (ESC).<sup>1,4</sup>

The prevalence of isolated non-compacted myocardium in adults remains unclear,<sup>1,3,4,6</sup> although observational

studies have found a prevalence of 0.01 to 0.26% in specialized services.<sup>1,2</sup>

However, the estimated prevalence may be higher, as asymptomatic individuals rarely undergo imaging studies.<sup>1</sup> In this context, we will address the case of an asymptomatic and previously healthy patient, who had high-incidence ventricular extrasystoles during the preoperative period and anesthesia induction for a cholecystectomy procedure.

## Case report

RASS, a 49-year-old female Caucasian patient, divorced, from Barra do Piraí, state of Rio de Janeiro, Brazil, a caregiver, with a diagnosis of cholelithiasis, had isolated, bigeminy ventricular extrasystoles during the preoperative examinations for a cholecystectomy procedure in August 2013. The procedure was cancelled, and the patient was referred to the cardiology outpatient clinic for assessment. She was asymptomatic and denied previous pathologies and medication use. She also denied smoking and alcohol consumption. She was unaware of heart disease in the family history. On physical examination, the patient had a third sound and frequent extrasystoles. She underwent a 12-lead resting electrocardiogram, which showed ventricular extrasystole and left atrial overload (Figure 1). Chest radiography showed no abnormalities.

Subsequently, she was submitted to an echocardiogram, which showed Left Atrium (LA) measuring 3.4 cm, Left Ventricular Diastolic Diameter (LVDD) of 6.1 cm and Left Ventricle Systolic Diameter (LVSD) of 4.7 cm; slightly thickened mitral valve; dilated cardiomyopathy with moderate LV systolic dysfunction; and ejection fraction

## Keywords

Heart Failure; Isolated Noncompaction of the Ventricular Myocardium; Arrhythmias, Cardiac; Tachycardia, Ventricular; Diagnostic Imaging.

**Mailing Address: Erivelton Alessandro do Nascimento**

Rua Gil Ferreira, 182, Jardim Primavera. Postal Code: 27283-570, Volta Redonda, RJ - Brazil.

E-mail: hpocrates7@gmail.com, hpocrates@cardiol.br

DOI: 10.5935/2359-4802.20190002

Manuscript received January 15, 2018; revised manuscript March 4, 2018; accepted March 13, 2018.

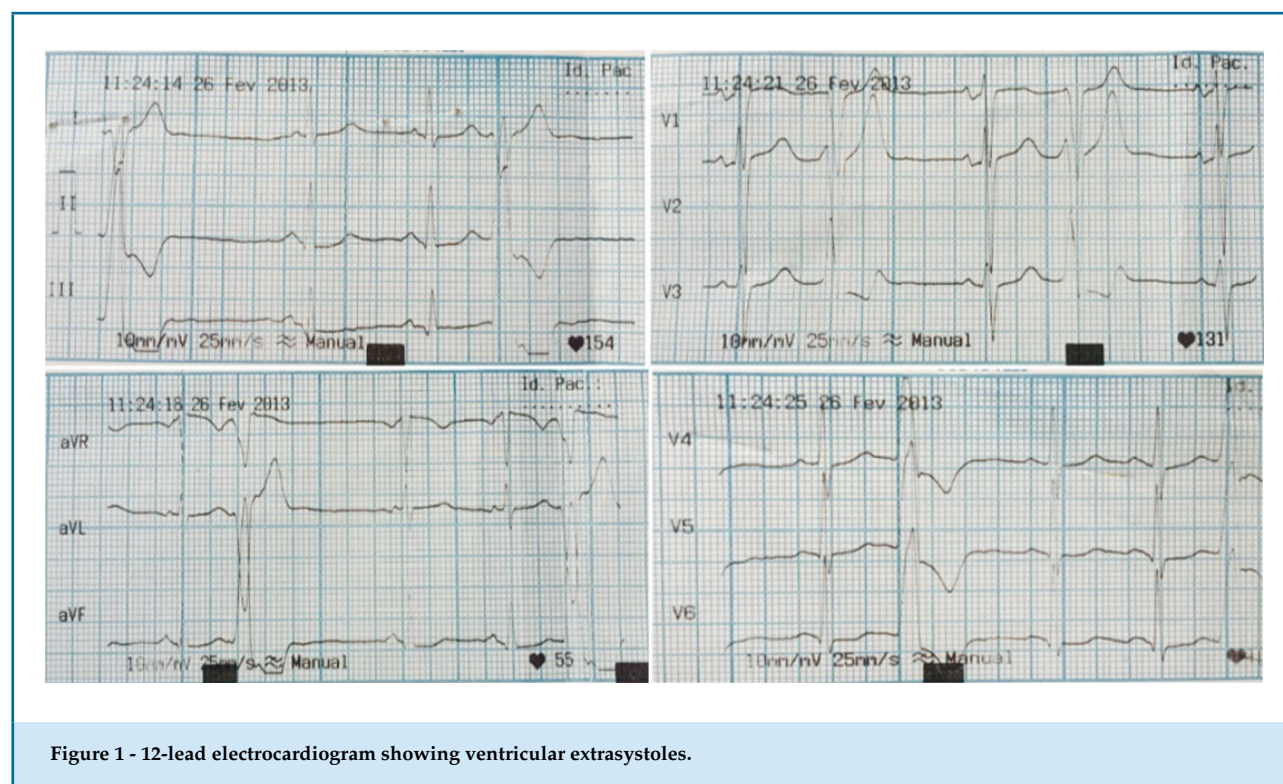


Figure 1 - 12-lead electrocardiogram showing ventricular extrasystoles.

of 46%. The 24-hour Holter showed the patient had 33,258 ventricular extrasystoles and one episode of non-sustained ventricular tachycardia.

The exercise test results showed sinus rhythm and presence of ventricular bigeminy in the pre-exertion phase, frequent ventricular extrasystoles, with a reduction of arrhythmias with isolated extrasystoles during the exertion. She was submitted to a coronary angiography, which did not show obstructive lesions. The patient started treatment for HF with optimized doses of carvedilol, enalapril and spironolactone.

In 2014, she was submitted to an echocardiogram, which showed inferomedial akinesia and mild LV systolic dysfunction. The 24-hour Holter showed a reduction in ventricular ectopies when compared to the initial exam, but still at high incidence (10,583 ectopies).

In 2015, the patient's systolic function normalized, but she still maintained the segmental alteration at the echocardiogram and the high incidence of ventricular ectopies. At that moment, she was submitted to a magnetic resonance imaging (MRI) assessment, which showed an increase in trabeculations in the LV mid-apical portion and a ratio between the non-compacted/compacted layers of 2.8 (1.4/0, 5 = 2.8) at the end of the diastole (Figures 2). These findings were compatible

with the diagnosis of left ventricular non-compaction cardiomyopathy.

The last evaluation occurred in 2017, and the patient was in New York Heart Association (NYHA) functional class I, with low-incidence ventricular ectopies and receiving warfarin anticoagulation.

## Discussion

During the embryonic development, the heart consists of a spongy network of muscle fibers and trabeculae, which are separated by recesses that connect the myocardium to the LV cavity. Blood is supplied to the myocardium through the intertrabecular spaces. Between the fifth and eighth weeks of fetal development, the ventricular myocardium undergoes compaction, with the transformation of the intertrabecular spaces into capillaries, and the residual spaces within the trabecular meshwork disappear. The process begins from the epicardium to the endocardium and from the base to the apex of the heart.<sup>2</sup> This trabeculation process is of utmost importance, since it allows a greater surface-to-volume ratio and an increase in muscle mass before coronary arteries are established.<sup>5,6</sup>

In the LV non-compacted myocardium, there is a persistence of the trabeculation and deep recesses,

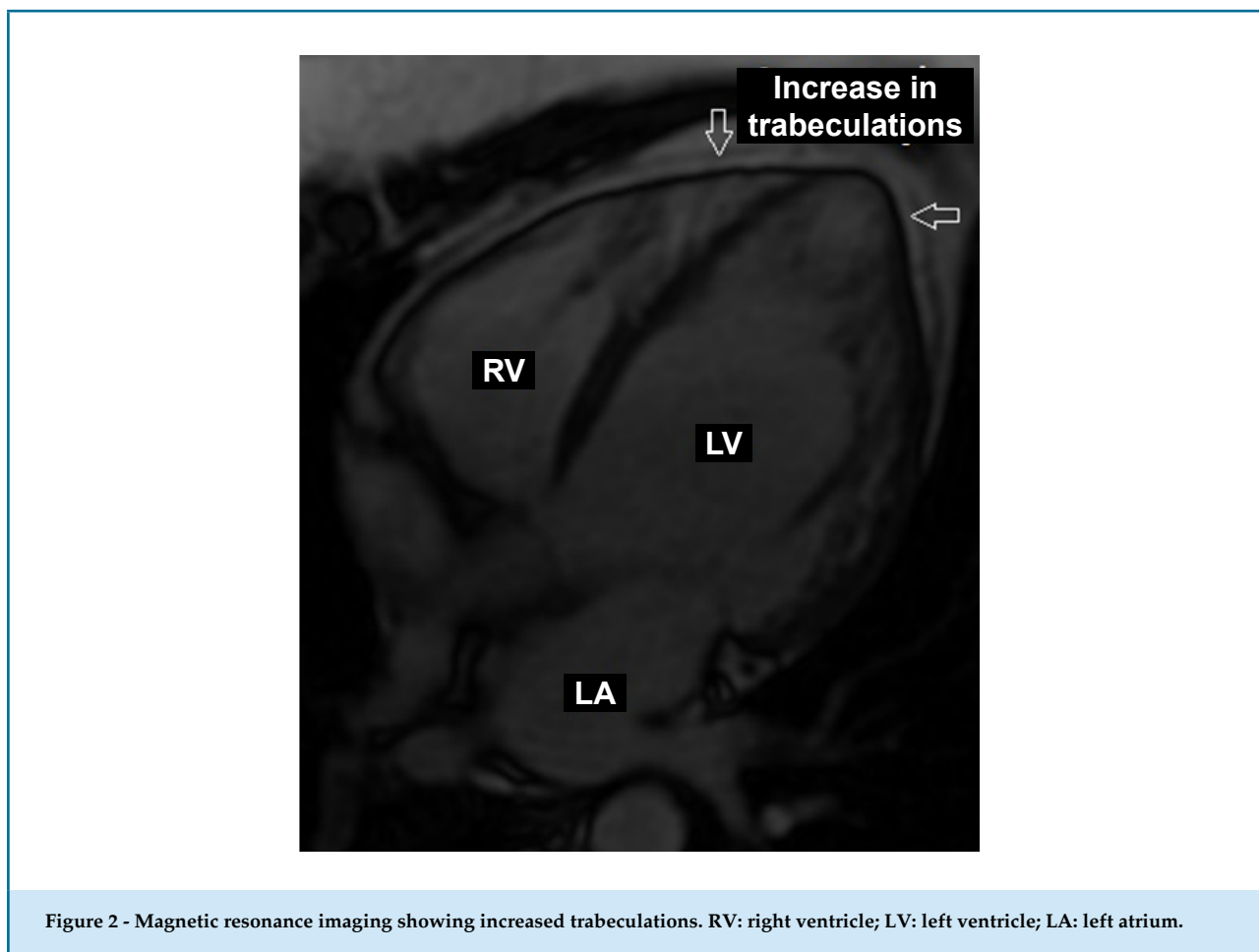


Figure 2 - Magnetic resonance imaging showing increased trabeculations. RV: right ventricle; LV: left ventricle; LA: left atrium.

which communicate with the ventricular cavity due to non-compaction.<sup>2</sup> Without the compaction completion, myocardial dysfunction occurs secondary to the failure of the efficient rotational ventricular system to develop contractile performance.<sup>5</sup>

The exact cause of the persistence of these trabeculations is unknown.<sup>1-3</sup> Studies point to familial recurrence of LV non-compacted myocardium.<sup>1,4</sup> The clinical status is variable, and it may be asymptomatic or present as heart failure, arrhythmias, thromboembolic events and sudden death.<sup>2,4,6</sup>

In the present report, the patient had ventricular arrhythmia and systolic heart failure as initial manifestations – found in more than 50% of the cases.<sup>2,4,6</sup> Ventricular arrhythmias were reported in 47% of adults.<sup>2</sup> Diastolic dysfunction occurs due to abnormal ventricular relaxation and restrictive filling caused by hypertrabeculation, whereas systolic dysfunction may result from subendocardial hypoperfusion and microcirculatory dysfunction.<sup>2,6</sup> Mechanical dyssynchrony

between the compacted and non-compacted myocardium may cause global LV dysfunction.<sup>2</sup>

Other rhythm abnormalities were also reported on the electrocardiogram, such as ST-segment depression and T-wave inversion, along with right-bundle branch block.<sup>2,4,6</sup>

In view of the diagnosis of LV systolic dysfunction associated with non-compacted myocardium, full anticoagulation therapy with warfarin was initiated. Associated thromboembolic events may be secondary to extensive ventricular trabeculation, atrial fibrillation, and decreased ventricular function,<sup>2,3</sup> which may lead to cerebrovascular accidents, transient ischemic attacks, pulmonary embolism, and mesenteric infarction.<sup>2,6</sup> Sudden death represents approximately 40% of cases of death in these patients.<sup>2</sup>

In the present clinical case report, the patient was asymptomatic. The findings of ventricular extrasystoles were incidentally found during a preoperative examination. The alterations found on the echocardiogram showed heart failure with reduced ejection fraction and

dilated cardiomyopathy, which was underestimated by the patient's clinical history, who was sedentary. With the start of the treatment for heart failure, there was ventricular function, normalization, but the ventricular arrhythmia persisted.

At this time, the possibility of prior myocarditis due to segmental alteration identified on the echocardiogram was suggested, and the arrhythmogenic substrate was seen as a ventricular reentry mechanism. The MRI, previously described as the gold standard imaging method, defined the diagnosis.<sup>4</sup>

We also emphasize that, despite the lack of an electrocardiographic presentation typical of Chagas disease, this is part of the differential diagnosis, mainly due to the ventricular arrhythmia manifestation. Zuccarino et al.<sup>4</sup> reinforce the importance of other imaging methods in the diagnosis of non-compacted myocardium, with echocardiography being the first-line examination, but with limitations in the visualization of non-compaction.<sup>4</sup> However, the three-dimensional echocardiography can facilitate the identification of non-compaction.<sup>7,8</sup>

## Conclusion

Left ventricular non-compaction cardiomyopathy can lead to fatal complications such as thromboembolic events, arrhythmias, and sudden death. These complications can be prevented with an early diagnosis and adequate treatment. Ventricular arrhythmias may be the initial

manifestation of the disease, and imaging tests play a key role in its diagnosis.

## Author contributions

Conception and design of the research: Nascimento EA, Santos RNC, Dutra FFT, Vitória MGI. Acquisition of data: Nascimento EA, Santos RNC, Dutra FFT, Vitória MGI. Analysis and interpretation of the data: Nascimento EA, Santos RNC, Dutra FFT, Vitória MGI. Writing of the manuscript: Nascimento EA, Santos RNC, Dutra FFT, Vitória MGI. Critical revision of the manuscript for intellectual content: Nascimento EA, Santos RNC, Dutra FFT, Vitória MGI.

## Potential Conflict of Interest

No potential conflict of interest relevant to this article was reported.

## Sources of Funding

There were no external funding sources for this study.

## Study Association

This study is not associated with any thesis or dissertation work.

## Ethics approval and consent to participate

All persons gave their informed consent prior to their inclusion in the study.

## References

- Ikeda U, Minamisawa M, Koyama J. Isolated left ventricular non-compaction cardiomyopathy in adults. *J Cardiol*. 2015;65(2):91-7.
- Udeoji DU, Philip KJ, Morrissey RP, Phan A, Schwarz ER. Left ventricular noncompaction cardiomyopathy: updated review. *Ther Adv Cardiovasc Dis*. 2013; 7(5):260-73.
- Shemisa K, Li J, Tam M, Barcena J. Left ventricular noncompaction cardiomyopathy. *Cardiovasc Diagn Ther*. 2013;3(3):170-5.
- Zuccarino F, Vollmer I, Sanchez G, Navallas M, Pugliese F, Gayete A. Left ventricular noncompaction: imaging findings and diagnostic criteria. *AJR Am J Roentgenol*. 2015;204(5):W19-30.
- Bennett CE, Freudenberger R. The current approach to diagnosis and management of left ventricular noncompaction cardiomyopathy: review of the literature. *Cardiol Res Pract*. 2016.2016:5172308.
- Bhogal S, Ladia V, Sitwala P, AlBalbissi K, Paul T. Isolated ventricular noncompaction cardiomyopathy presenting as recurrent syncope. *Case Rep Med*. 2016.2016:3742171
- Baker G, Pereira N, Hlavacek A, Chessa K, Shirali G. Transthoracic real-time three-dimensional echocardiography in the diagnosis and description of noncompaction of ventricular myocardium. *Echocardiography*. 2006; 23(6): 490-4.
- Engberding R, Stöllberger C, Ong P, Yelbuz T, Gerecke B, Breithardt G. Isolated noncompaction cardiomyopathy. *Dtsch Arztebl Int*. 2010;107(12):206-13.

