

CASE REPORT

Hypertrophic Cardiomyopathy, All Phenotypes in one

Aníbal M. Arias, Diego Perez de Arenaza, Rodolfo Pizarro, Ricardo G. Marenchino, Fernando Garagoli, Hernán García Rivello, César Belziti

Hospital Italiano de Buenos Aires, Buenos Aires - Argentina

Introduction

Hypertrophic cardiomyopathy (HCM) is an intrinsic myocardial disorder characterized by cardiac hypertrophy (wall thickness ≥ 15 mm), that is not explained by conditions of pressure overload (eg, hypertension, severe aortic stenosis).¹ HCM is the most common genetic primary cardiomyopathy, with a prevalence estimated to be about one in 500 adults in the general population.²

More than 450 mutations have been identified in the 20 genes that cause different phenotypes. In most cases, HCM is associated with sarcomere protein gene mutations, and exhibits multiple phenotypic expressions. We present a case that combines all phenotypes.³

Case Report

A 58-year-old hypertensive woman was admitted to the coronary care unit because of acute heart failure syndrome. The patient denied chest discomfort, illicit drug use or previous disease. The patient noted progressive dyspnea, abdominal swelling, edema of both legs and weight gain. Bilateral edema, ascites, jugular venous distention and (a 3-sound) gallop rhythm were evident on physical examination. The electrocardiogram (ECG) showed sinus rhythm, low QRS amplitude and a pseudoinfarction pattern (Figure 1). The echocardiogram depicted global severe hypokinesis with preservation of lateral wall motion, and increased wall thickness with left chamber enlargement. Moderate pericardial effusion was also present. A continuous infusion of loop diuretics was administered.

Keywords

Cardiomyopathy, Hypertrophic; Heart Failure; Cardiomegaly; Heart Transplantation.

Thyroid hormones, iron tests and free light chain proteins were negative. Coronary angiography showed normal coronary arteries.

Cardiac magnetic resonance revealed maximal wall thickness of 15 mm, left ventricular (LV) mass 262 g and LV mass index 178 g/m², LV diastolic volume 194 mL, LV systolic volume 167 mL and ejection fraction 14%. A marked, diffuse transmural late gadolinium enhancement was also detected (Figure 2. A-F) (Video 1).

With the picture of severe congestive heart failure in addition to an inverse relationship of ECG amplitude with wall thickness, an infiltrative cardiomyopathy was suspected. Right heart catheterization showed high filling pressures and low cardiac output, and endomyocardial biopsy showed diffuse fibrosis without specific changes. As the patient became refractory to optimal medical treatment, she underwent orthotopic heart transplantation. She recovered uneventfully and biopsy of the explanted heart was positive for HCM, showing severe interstitial fibrosis and extensive foci of myocyte disarray affecting the LV (Figure 2.G).

Discussion

HCM is a heterogeneous disease in terms of both genetics and phenotypes. For instance, it has been reported that distribution of hypertrophy in hypertrophic cardiomyopathy by troponin T gene differs not only among families but also within families.⁴

The information available about the genotype - phenotype correlation in HCM is sparse.

Sometimes HCM exhibits a "restrictive phenotype" characterized by restrictive filling and minimal or no left ventricular hypertrophy, which resembles idiopathic restrictive cardiomyopathy.⁵

Mailing Address: Fernando Garagoli

Peron, 4190. Postal Code: C1183AEG, Almagro, Ciudad Autónoma de Buenos Aires, Buenos Aires – Argentina.
E-mail: fernando.garagoli@hospitalitaliano.org.ar

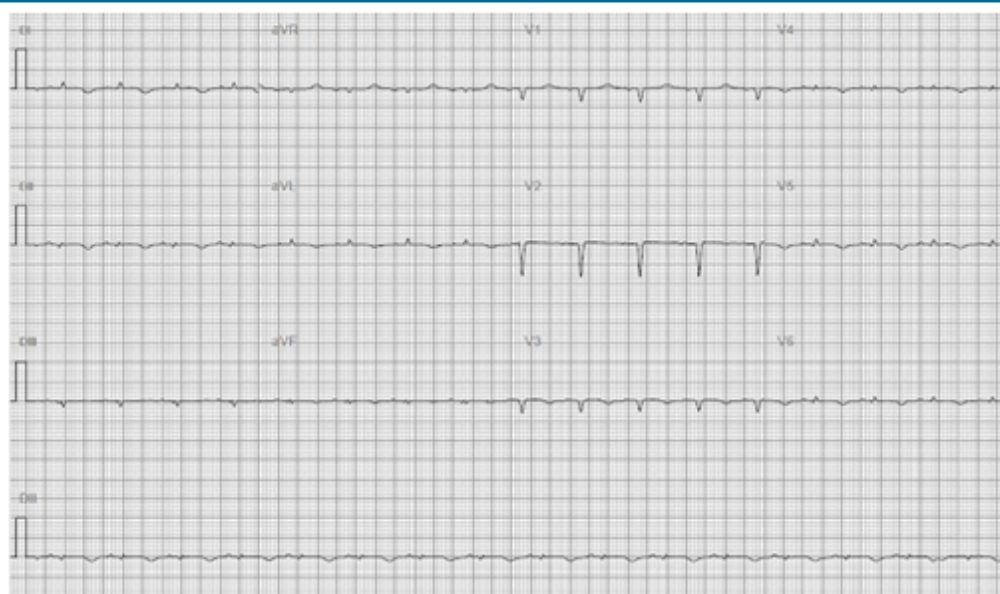

Figure 1 – The electrocardiogram (ECG) showed sinus rhythm, low QRS amplitude and a pseudoinfarction pattern.

A smaller number of patients with HCM (5-10%) will progress to an end-stage form of the disease that is characterized by LV dilation, wall thinning and systolic dysfunction.⁶ Despite the absence of systemic disease, the relationship between increased wall thickness, low ECG amplitude and severe diastolic dysfunction favors the diagnosis of a restrictive cardiomyopathy. Gadolinium enhancement was also typical for cardiac amyloidosis. In addition, there was no history of familial cardiac disease. Although endomyocardial biopsy even ruled out the diagnosis of cardiac amyloidosis, it also failed to confirm HCM, probably because the right ventricle was less affected.

In this case, we reported increased left ventricular dimensions, depressed systolic function, ventricular hypertrophy and restrictive physiology, which are typical of a dilated, restrictive, hypertrophic phenotype. It is known that multiple genetic mutations can be present in the same person, which might explain the combination of three different features in this case.

There is no similar case report in the literature.

The limitation of this report is that we could not perform genetic testing as it is not currently available at our institution. In addition to the HCM diagnosis provided by biopsy it would have been of great value to know the specific gene mutation in order to puzzle out this “intriguing phenotype”.

Author contributions

Conception and design of the research: Arias AM, Arenaza DP, Pizarro R, Marenchino RG, Garagoli F, Rivello HG, Belziti C. Acquisition of data: Arias AM, Arenaza DP, Pizarro R, Marenchino RG, Garagoli F, Rivello HG, Belziti C. Analysis and interpretation of the data: Arias AM, Arenaza DP, Pizarro R, Marenchino RG, Garagoli F, Rivello HG, Belziti C. Statistical analysis: Arias AM, Arenaza DP, Pizarro R, Marenchino RG, Garagoli F, Rivello HG, Belziti C. Writing of the manuscript: Arias AM, Arenaza DP, Pizarro R, Marenchino RG, Garagoli F, Rivello HG, Belziti C. Critical revision of the manuscript for intellectual content: Arias AM, Arenaza DP, Pizarro R, Marenchino RG, Garagoli F, Rivello HG, Belziti C.

Potential Conflict of Interest

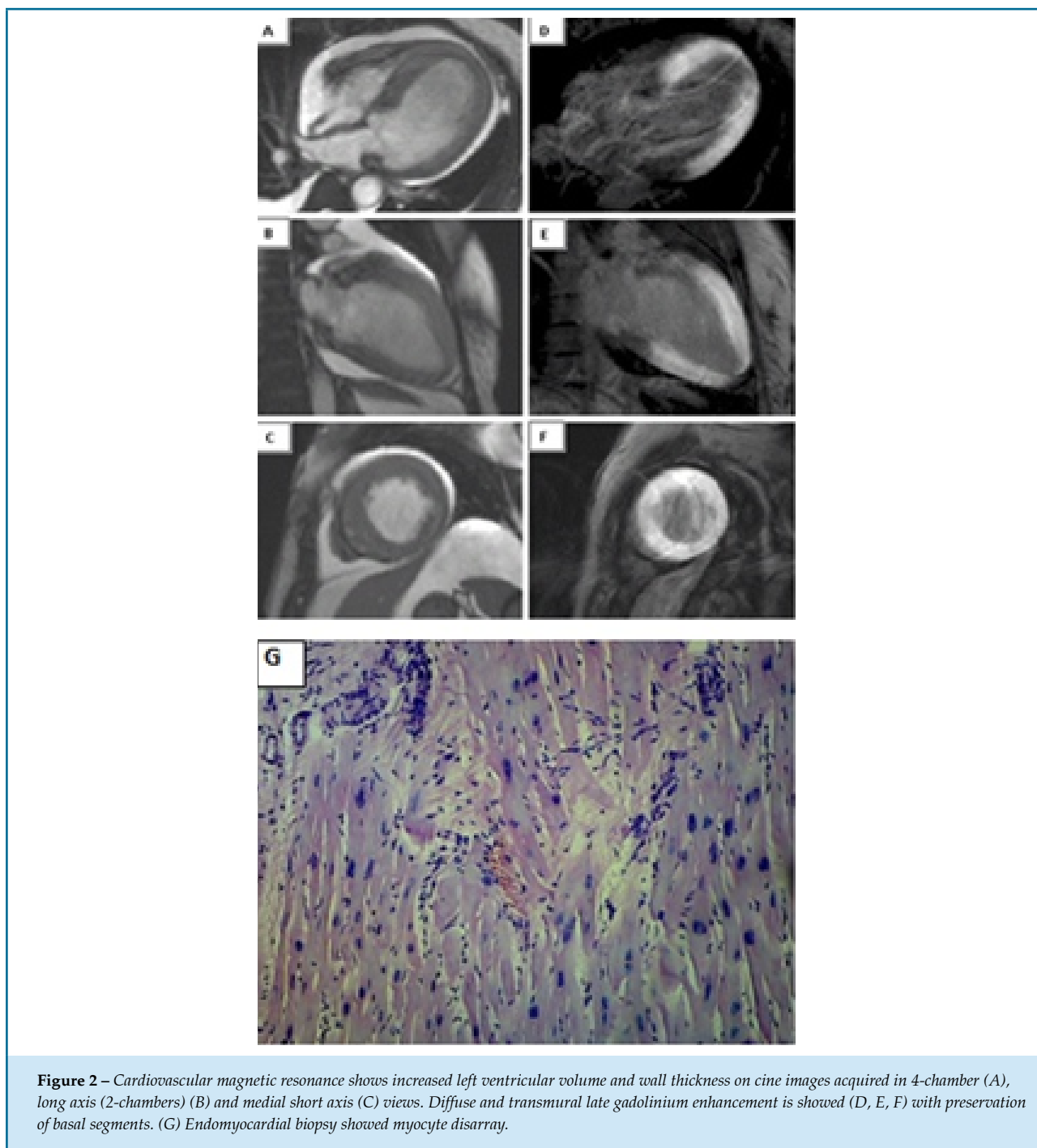
No potential conflict of interest relevant to this article was reported.

Sources of Funding

There were no external funding sources for this study.

Study Association

This study is not associated with any thesis or dissertation work.



References

1. Task Force Members. Elliott PM, Anastasakis A, Borger MA, Borggrefe M, Cecchi F, Charron P, et al. 2014 ESC Guidelines on diagnosis and management of hypertrophic cardiomyopathy: the task force for the diagnosis and management of hypertrophic cardiomyopathy of the European Society of Cardiology (ESC). *Eur Heart J*. 2014; 35(39): 2733–79. DOI: 10.1093/euheartj./Orgv-Ejehu284.
2. Lipshultz SE, Sleeper LA, Towbin JA, Lowe AM, Cox GF, Lurie PR, et al. The incidence of pediatric cardiomyopathy in two regions of the United States. *N Engl J Med*. 2003;348(17):1647-55. DOI: 10.1056/NEJM.0a21715.
3. Ho CY, Charron P, Richard P, Garolami F, Van Spaendonck-Zwarts KY, Pinto Y. Genetic advances in sarcomeric cardiomyopathies: state of the art. *Cardiovasc Res* 2015; 105: 397–408. DOI: 10.1093/cv/cvv025.
4. Anan R, Shono H, Kisanuki A, Arima S, Nakao S, Tanaka H, et al. Patients with familial hypertrophic cardiomyopathy caused by a Phe110Ile missense mutation in the cardiac troponin T gene have variable cardiac morphologies and a favorable prognosis. *Circulation*. 1998;98(5):391–7. PMID:9714088.

-
5. Kubo T, Gimeno JR, Bahl A, Steffenson U, Osman E, Thaman R, et al. Prevalence, Clinical Significance, and Genetic Basis of Hypertrophic Cardiomyopathy With Restrictive Phenotype. *J Am Coll Cardiol* 2007;49(25):2419–26. DOI: 10.1016/j.jacc.2007.02.061.
 6. Harris JK, Spirito P, Maron MS, Zenovich AG, Formisano F, Lesser JR, et al. Prevalence, clinical profile, and significance of left ventricular remodeling in the end-stage phase of hypertrophic cardiomyopathy. *Circulation* 2006;114(3):216–25. DOI: 10.1161/CIRCULATIONAHA.105.583.500.

