

Challenging Diagnosis of Myocardial Infarction Due to Anomalous Left Circumflex Artery

Maksymilian P. Opolski,¹ Kajetan Grodecki,² Mateusz Spiewak,¹ Mariusz Furmanek,³ Ilona Michalowska¹

Institute of Cardiology,¹ Warsaw – Poland

Medical University of Warsaw,² Warsaw – Poland

Medical Center for Postgraduate Education,³ Warsaw – Poland

A 45-year-old male without past medical history presented with retrosternal chest pain and ST-segment elevation in inferolateral leads at ECG. Invasive coronary angiography, along with optical coherence tomography performed as part of the clinical study, showed normal coronaries, and myocardial infarction with non-obstructive coronary arteries (MINOCA) was diagnosed (Figure 1 A-B). Due to ongoing chest pain, triple-rule-out computed tomography angiography (CTA) was undertaken to exclude aortic dissection and pulmonary embolism. Incidentally, anomalous left circumflex artery (LCx) originating from the right sinus of Valsalva with a suspicion on severe stenosis was detected (Figure 1 C-E). Selective angiography of the LCx confirmed severe lesion in the distal vessel segment (Figure 1 F), however given the resolution of patient's symptoms, a decision on medical therapy with dual antiplatelet agents was undertaken. At discharge, cardiac magnetic resonance disclosed mildly reduced left ventricular ejection fraction (53%) with myocardial edema and transmural infarction of the basal-to-mid lateral wall (Figure 1 G-H).

LCx arising from the right aortic sinus is the most frequent coronary artery anomaly (CAA) found in up to 0.7% of the population. Although anomalous LCx is considered benign, the severe angle and tortuous vessel course may

predispose it to accelerated atherosclerosis. Herein, the anomalous LCx was overlooked due to super-selective cannulation of the right coronary artery, and a large intermediate branch was incorrectly classified as LCx leading to deferred revascularization and irreversible myocardial injury. This case highlights that CAA could be included in the differential diagnosis of MINOCA, and unveils the potential for triple-rule-out CTA in detecting CAA.

Author contributions

Conception and design of the research: Opolski MP, Spiewak M; Acquisition of data: Opolski MP, Spiewak M, Furmanek M, Michalowska I; Analysis and interpretation of the data and critical revision of the manuscript for intellectual content: Opolski MP, Grodecki K, Spiewak M, Furmanek M, Michalowska I; Obtaining financing: Opolski MP; Writing of the manuscript: Opolski MP, Grodecki K.

Potential Conflict of Interest

No potential conflict of interest relevant to this article was reported.

Sources of Funding

This study was partially funded by Research Grant "Iuventus Plus" from the Polish Ministry of Science and Higher Education [IP2014 034073].

Study Association

This study is not associated with any thesis or dissertation work.

Keywords

Myocardial Infarction / Diagnosis; Coronary Artery Anomalies; Coronary Angiography; Cardiac Magnetic Resonance.

Mailing Address: Maksymilian P. Opolski •

Alpejska 42, 04-628, Warsaw – Poland

E-mail: opolski.mp@gmail.com, maxopol@gmail.com

Manuscript received August 19, 2017, revised manuscript December 12, 2017, accepted December 12, 2017

DOI: 10.5935/abc.20180093

Image

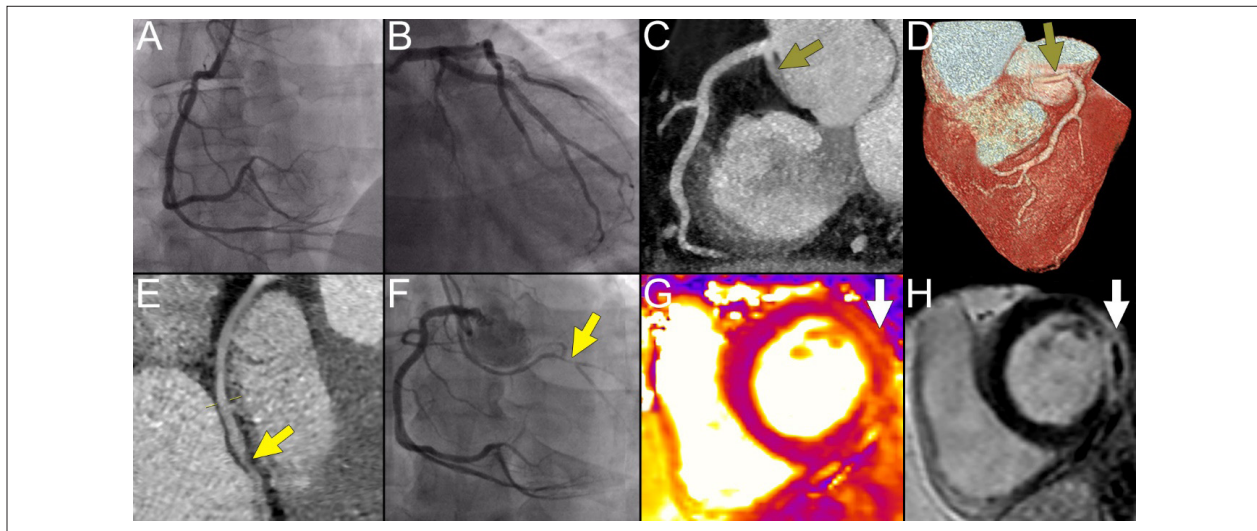


Figure 1 – Coronary angiography, coronary computed tomography angiography and cardiac magnetic resonance findings of the patient with challenging diagnosis of myocardial infarction and anomalous left circumflex artery.



This is an open-access article distributed under the terms of the Creative Commons Attribution License